

Experience Using Long-Wave Ultrasonic Stimulator for Canine Tumors (Is Dolphin Waves Effective for Canine Tumors?)

Research Article

Volume 3 Issue 1- 2024

Author Details

Hiroko Fujii¹, Yoshio Shimotori^{2*} and Meizo Kusaka³

¹Director of R&D, DP Labo, Japan

²Research and Development Center, President of Kamiyama, Limited, Japan

³Director of R&D, World brain, Co Limited, Japan

*Corresponding author

Yoshio Shimotori, Research and Development Center, President of Kamiyama, Limited, Japan

Article History

Received: : March 02, 2024 Accepted: March 05, 2024 Published: March 07, 2024

Abstract

We attempted to examine the effects of weak ultrasonic stimulation on a dog (Toy Poodle, male, 12 years old) whose removal through open surgery is difficult. We report a case in which a dog that was given only three months to live survived a tumor and its life was extended for two years and five months. One elderly male Toy Poodle (12 years old) underwent laparotomy due to suspected gastrointestinal tumors, but was diagnosed as inoperable due to multiple tumors. As a result, the dog was diagnosed with only three months left to live. Two weeks later, the melena and anemia worsened, so a dog started taking prednisone. In combination with the drug, ultrasonic stimulation was applied twice daily (5 minutes each, 10 minutes/day in total) to the affected area of the back body. A transverse colon mass was observed 2 months after starting treatment, and a peripheral lymph node tumor was observed 5 months later. One year later, decreased appetite, bloody stool, vomiting, and numerous tumors were observed. One year and 3 months later, an aortic tumor thrombus was confirmed, and the PCV (Packed Cell Volume) was 15%. The dog did not suffer and died 2 years and 5 months later. Ultrasonic treatment is thought to be useful in prolonging the survival of dogs with tumors.

Keywords: Long-Wave Ultrasonic Stimulation, Dog, Tumor

Preface

We have developed a low-frequency ultrasonic stimulation device that focuses on the frequency band emitted by dolphins in the ocean. A clinical trial was conducted on a dog tumor based on the concept of vibrating capillaries, nerve cells, and bones with weak long-wave ultrasound stimulation. This device applied ultrasonic stimulation to the tumor site in dogs from the back. The ultrasonic frequency is 30KHz (0.03MHz), which is a non-standard ultrasonic frequency for medical equipment. The wavelength inside the body (simulated in water) is approximately 5cm, and it is characterized by a low attenuation rate of propagation within the body and good penetration of acoustic vibrations. The speed of sound propagation in the air is approximately 340meters/second. The dog's body contains a lot of water, just like the human body, and the speed of sound is approximately 1,500me-

ters/second, considering it to be propagated through water, while it is estimated to be 5,000meters/second in bones, so sound vibrations are transmitted well within the dog's body. It is thought that motor stimulation of capillaries and neurons can be obtained with vibrational energy of several microwatts/cm². It is also often transmitted to the ribs that surround the lungs. The sound intensity in this clinical test is less than 1.6mw/cm². The intensity of this ultrasonic wave is approximately 1/10,000 or less of the intensity that causes cavitation.

In preliminary human clinical studies, we confirmed that stimulating the capillaries and nerve cells in the brain with weak ultrasound waves for 20 minutes increases cerebral blood flow [1,2]. Furthermore, efficacy and safety were confirmed in clinical trials for cranial nerve diseases [3-6]. Subsequent clinical trials conducted on patients with temporomandibular joint disorders and lung cancer also confirmed its efficacy and safety [7-9]. This time, we conducted a case study on dog



tumors using a long-wave ultrasound stimulation device developed by Ueyama Seisakusho Co., Ltd. We will briefly introduce the report.

Subject and Method

Subject

One elderly male Toy Poodle (12 years old) underwent laparotomy due to suspected tumors, but was diagnosed as inoperable due to multiple tumors. As a result, the dog was diagnosed with only three months left to live.

Table 1: Specifications.

Items	Specifications
Rated voltage, current	AC 100v 0.2A
Ultrasonic output	30kHz, 0.001W/sec, Each vibrator
Type of treatment head	Pulse stimulation on left and right alternately, 10% pulse ratio
Timer	5 minutes

Usage method

Ultrasound was irradiated from the dorsal surface of the affected area and used twice a day, once in the morning and once in the evening, for 5 minutes each. The irradiation intensity for dogs was 1mW/

Design

Since the subject of this research is observational research, it was designated as a case study. Treatment was performed after obtaining written consent for treatment from the owner. The animal was treated at an animal hospital near Tokyo.

Testing device

Test equipment was lent to the dog’s owner, and ultrasound was applied to the dog until just before it died. Specifications are shown in Table 1.

sec, which was set at half power of the intensity used in human clinical research (1.6mW) based on the human-to-dog volume ratio. The test equipment (Figure 1) and ultrasonic transducer belt (Figure 2) are shown below.

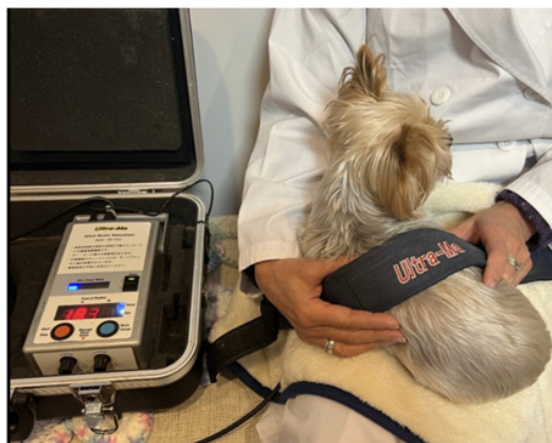

Figure 1: Ultrasonic stimulation treatment style (ultrasonic transducers are placed on the left and right sides of the spine, and ultrasound stimulation is applied alternately).



Figure 2: Ultrasonic vibrator belt and resin ultrasonic vibrator.



Testing Schedule

A dog was brought to a veterinary hospital with diarrhea-like bloody stools. As a result of open surgery, the veterinarian determined that it would be difficult to remove the tumor, so they decided not to perform surgery to remove the tumor. Two weeks after diagnosis, we started using a long-wave ultrasound stimulator. During the trial period of the long-wave ultrasound stimulator, an X-ray examination (after 1 year and 2 months), 3 ultrasound examinations (after 3 months, 1 year and 1 month, and 1 year and 3 months), and blood tests were conducted.

Observation Items

Home: Symptom Observation in Daily Life

Appetite, health condition, presence or absence of bloody stool, etc.

Hospital: Regular Health Check

- Necessary tests for progress report at home (appetite, stool)
- Ultrasound imaging
- Blood Test

WBC, RBC, Hb, PCV, MCV, MCH, MCHC, Platelet Count

Safety

Safety was confirmed regarding adverse events and device malfunctions during the period of use.

Result

General Symptoms

A dog had diarrhea-like bloody stools and was taken to a veterinary

hospital. Abdominal ultrasound imaging revealed disruption of the five-layer structure near the ileocecal area and full-thickness thickening, and aplastic anemia was confirmed with a PCV of 22.3% (blood test). Afterwards, an endoscopy of the lower gastrointestinal tract and cytology under ultrasound imaging were performed. As a result, epithelial cell carcinoma and lymphoma were ruled out. Laparotomy was performed and an ileocecal mass and all mesenteric lymph node tumors were confirmed. It was determined that the tumor would be difficult to remove, so surgery to remove the tumor was abandoned.

Two weeks later, the melena and anemia worsened, so a dog started taking prednisone. In combination with the drug, ultrasound stimulation was started twice a day (5 minutes each, for a total of 10 minutes) from the surface of the affected back body. Thereafter, the melena and anemia gradually improved, and the patient's condition was stable, but a mass was also found in the transverse colon. Two years and three months after treatment, bloody stools were observed, the patient's symptoms were debilitating, and the PCV was 15%. Two years and five months later he died.

X-Ray Results

The X-ray test was conducted 1 year and 2 months after treatment (Figure 3).

Physician's opinion: It was confirmed that there was no metastasis to the lungs.

Laparotomy (Initial)

(Figure 4) Physician's opinion: An ileocecal mass and enlarged mesenteric lymph nodes were confirmed, as well as adhesion to the duodenum. It was determined that the tumor would be difficult to remove, so surgery to remove the tumor was abandoned.

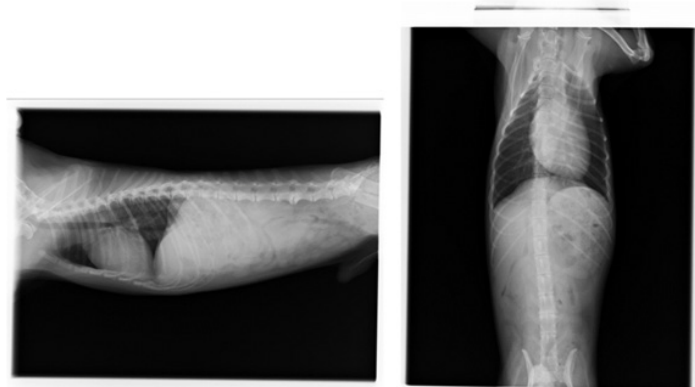

Figure 3: X ray imaging.

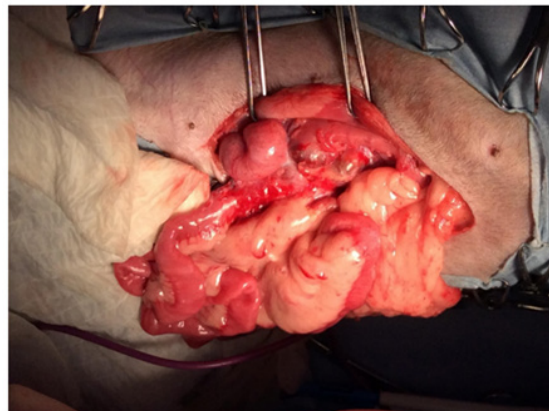


Figure 4: Laparotomy.



Ultrasound Imaging Diagnosis

Longwave ultrasound stimulator: Before use

Physician's opinion: It can be seen that the intestinal wall has become thicker.

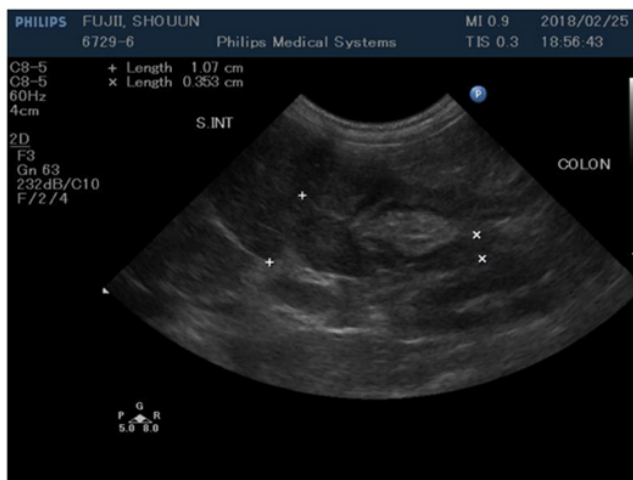


Figure 5: Ultrasound imaging diagnosis.

Long wave ultrasonic stimulator: Immediately after use

Physician's opinion: It can be seen that the intestinal wall has become thicker.

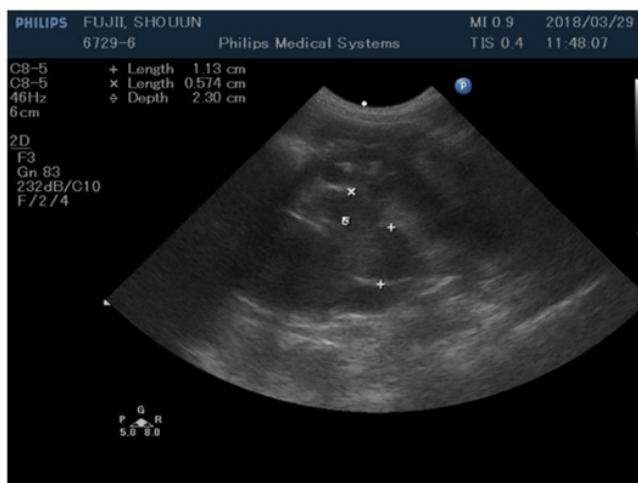


Figure 6: Ultrasound imaging diagnosis.

After using the long-wave ultrasound stimulator: 3 months after treatment

Physician's opinion: No change in intestinal wall

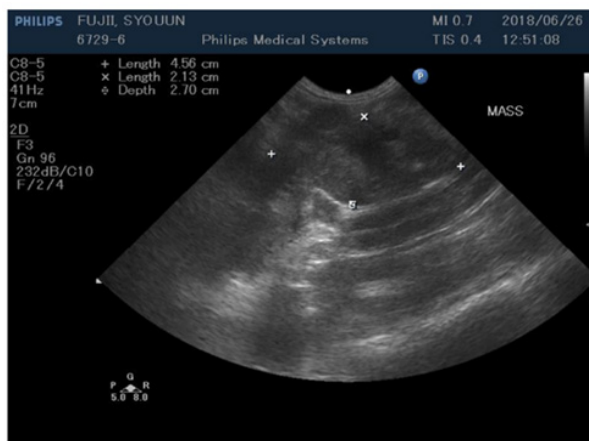


Figure 7: Ultrasound imaging diagnosis.



After using the long-wave ultrasound stimulator: 1 year and 1 month after treatment

Physician's opinion: There was no change in the lump. No ascites or intestinal obstruction

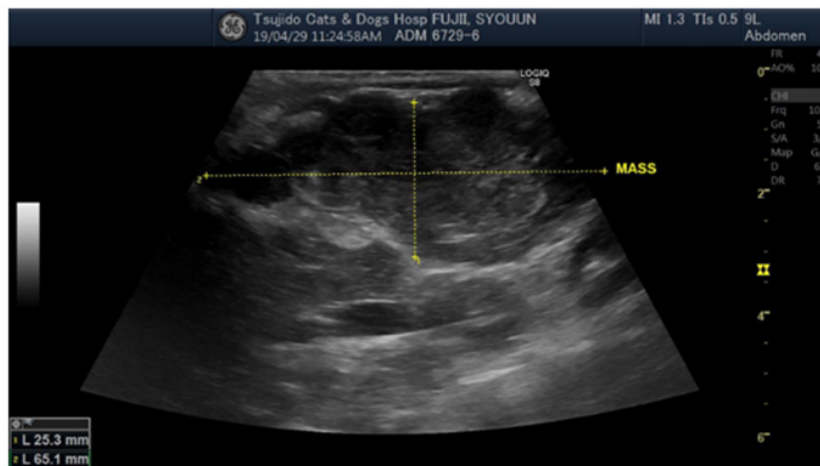


Figure 8: Ultrasound imaging diagnosis.

After using the long-wave ultrasound stimulator: 1 year and 3 month after treatment

Physician's opinion: Thrombus 15x30 was confirmed in the blood vessel.

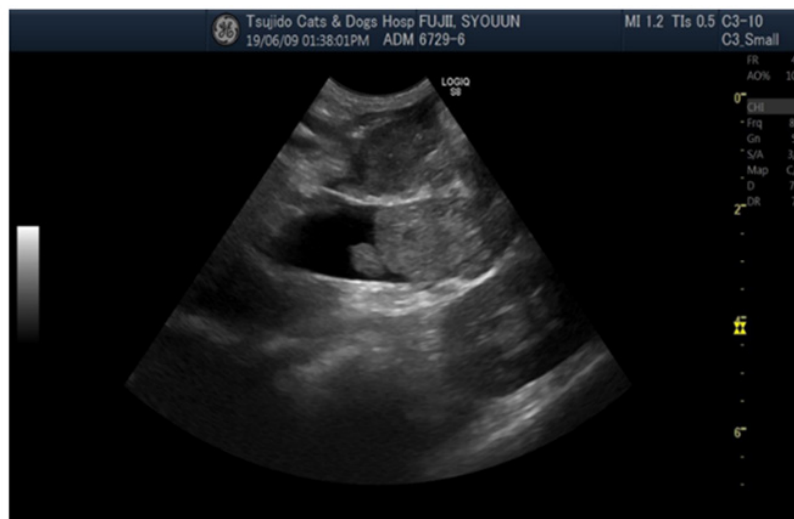


Figure 9: Ultrasound imaging diagnosis.

Blood test

Table 2:

Items	Reference values	Initial diagnosis	2 weeks later	3 months later	1 year and 1 month later	1 year and 3 months later
WBC	60-170	160	189	125	231	95
RBC	550.0-850.0	462	392	552	472	319
Hb	12.0-18.0	7.5	6.2	8.1	8.1	4.4
PCV	37.0-55.0	24.3	21.2	26.1	24.8	15.1
MCV	60.0-77.0	52.6	54.1	47.3	52.5	47.3
MCH	19.5-24.5	16.2	15.8	14.7	17.2	13.8
MCHC	32.0-36.0	30.9	29.2	31	32.7	29.1
Platelet Count	20.0-50.0	49.5	85.2	73.5	47.2	47.1

Normal range **Above normal**



Safety

Since there were no adverse events and no reports of malfunctions with this device, it was considered that there were no safety issues with this device.

Conclusion

This time, Fujii et al. conducted a case study of an ultrasound stimulation device for canine tumors. The dog was suspected to have gastrointestinal cancer, so laparotomy was performed, but the attending physician determined that surgery was inoperable due to multiple nodules in the dog's gastrointestinal tract. Based on abdominal findings at the time of surgery, his doctor gave him three months to live, but with the use of an ultrasound stimulator, his life was extended by two years and five months. Looking at the dog's progress after using the ultrasound machine, there was a period when the dog's symptoms remained stable for a while. However, during that period, a mass was also found in the transverse colon, and surrounding lymph nodes were also enlarged. Two years after the start of ultrasound treatment, bloody stools were observed, the symptoms became debilitating, and the PCV was 15%. Later, a tumor thrombus was confirmed in the aorta, and the PCV was 10%. A dog died at the age of 14 years and 4 months.

According to the dog's owner, when it was time to use the test device, the dog came to the owner, asked the owner to put it on, and lay down comfortably. In other words, it seems that the dogs had a high quality of life. It is noteworthy that the dog, who was given only three months to live, survived for two years and five months after using an ultrasound machine. The owner said his wish was for the dog to live out its lifespan without compromising its quality of life. There were no adverse events believed to be related to the test device during the study period, and no adverse effects on dogs were observed. Since there were no reports of malfunctions with this device, it was considered that this device could be used safely in dogs with tumors. It is hoped that by using this device, people will be able to spend time with their pets in a fulfilling way, with the goal of living a long and peaceful life without suffering. It would be of great significance if the ultrasonic stimulator (Ultra-Ma) could be used as an adjunctive therapy to extend the period from tumor confirmation to death in dogs.

References

1. Okano S, Shimotori Y (2015) Measurement of sound field of ultrasound massager for the head in skull model: *Iiryo kiki gaku* 85: 14-21.
2. Okano S, Shimotori Y (2015) Changes of Cerebral Blood Flow by the Weak Trans-Cranial Ultrasound Irradiation in Healthy Adult Volunteers: *Japanese Journal of Complementally and Alternative Medicine* 12: 73-78.
3. Manabe Y, Shimotori Y (2023) A clinical study on the efficacy and safety of the head ultrasonic stimulator Ultra-Ma for patients with clinically diagnosed dementia with Lewy bodies: *Clinical Study Report*.
4. Fujii H, Shimotori Y (2021) Reduction of dementia symptoms by weak transcranial ultrasound therapy. *Japan Society for Dementia Prevention* 11: 49-57.
5. Fujii H, Shimotori Y (2022) Effects of Transcranial Weak Ultrasonic Stimulation on Parkinson's Symptoms-Consideration Focused on Cognitive Function Tests *Japanese Journal of Complementally and Alternative Medicine* 19(2): 97-101.
6. Yoshio Shimotori, Meizo Kusaka (2023) Efficacy and Safety of Low-Level Long-Wave Ultrasonic Stimulator for Dementia with Lewy Bodies and Parkinson's Disease (Is the Dolphin Wave Effective for Neurodegenerative Diseases in the Brain!). *J Clin Res Med*, Volume 6(2): 1-5.
7. Hiroki Morinaga, Takeshi Kaneko, Meizo Kusaka, Yoshio Shimotori, Yousuke Naito (2022) Effectiveness for temporomandibular joint disease masticatory muscle pain disorder by using ultrasonic stimulator "Ultra-Ma": *Medical Consultation and New Remedies* 59: 315-333.
8. Yoshio Shimotori, Meizo Kusaka (2023) Report on the effectiveness of long-wave ultrasonic stimulation for patients with temporomandibular joint disease and masticatory muscle pain disorder (Is dolphin waves effective for temporomandibular joint disease?). *Journal of Dental and Maxillofacial Research* 3(2).
9. Hiroko Fujii, Yoshio Shimotori, Meizo Kusaka (2023) Advanced lung cancer patients: Palliative care efficacy trial using long-wave ultrasound stimulation / 7 cases (Is Dolphin Waves Effective for Patients with Lung Cancer?). *International Journal on Respiratory Care and Medicine* 1(1).

