

Successful Uterus Conservation Surgery of Focal Placenta Accreta Spectrum Disorders in National Referral Center in Indonesia, Cipto Mangunkusumo National Hospital: A Case Series Study

Review Article

Volume 6 Issue 1- 2026

Author Details

Fita Maulina^{1*}, Mohammad Adya Firmansha Dilmy², Yudianto Budi Saroyo², Yuditia Purwosunu²

¹Resident of Obstetrics, Gynecology Faculty of Medicine Universitas Indonesia

²Consultant of Obstetrics, Gynecology Faculty of Medicine Universitas Indonesia

*Corresponding author

Fita Maulina, Faculty of Medicine Universitas Indonesia, Salemba Raya Street Number 6, Kenari, Senen, Central Jakarta 10430

Article History

Received: March 03, 2026 Accepted: March 12, 2026 Published: March 23, 2026

Abstract

Conservative surgery (uterus sparing) of placenta accreta spectrum disorders (PASD) consists of all procedures that spares the uterus aiming to avoid morbidity such as massive intraoperative blood loss, prolonged surgery time, and other surgical complications associated with peripartum hysterectomy in appropriate cases. This article aims to report and share successful uterus conservation surgery technique of focal placenta accreta. The study was conducted in Cipto Mangunkusumo National Hospital, Jakarta from January 2017 to July 2019.

This is a case series of 3 cases of pregnant women that were previously diagnosed with PASD in our national hospital. We collected data of the maternal outcomes including duration of surgery, intraoperative bleeding, length of hospitalization, and the technical steps of the procedures. Conservative surgery for the management of focal PASD using Jakarta surgical uterus conservation surgery for placenta accreta (JSICA) technique is feasible and may have advantages in the management of focal PASD by decreasing surgery time, intraoperative bleeding, and ICU admission in selected cases. Larger prospective controlled trials are required to confirm its advantage.

Keywords: Placenta Accreta Spectrum Disorders, Jakarta Surgical Uterus Conservation Surgery For Placenta Accreta

Background

Placenta accreta spectrum disorders (PASD) is a pregnancy complication in which the placenta or trophoblast invasion exceeds the normal depth of uterine layer. In PASD, the placenta penetrates the decidua, myometrium and sometimes uterine serous. Cases of PASD are often accompanied by complications of massive bleeding (mean of 2110ml), emergency hysterectomy, intensive care (48%), and even maternal death (3.7%). PASD can be classified according to 2 classifications based on the depth of placental invasion; accreta, inkreta, and percreta and based on broad invasion; focal or diffuse.

The maternal mortality rate is as high as 305 per 100,000 births in Indonesia and around one third of maternal deaths are caused by obstetric bleeding. The increasing incidence of PASD has become a

concern among obstetricians in the world. As a tertiary and national referral center, Cipto Mangunkusumo National Hospital must be prepared with cases of obstetric surgery with a high degree of difficulty if it wants to play its role in efforts to reduce maternal mortality in Indonesia. Therefore the obstetrics and gynecology department decides the formation of the "PASD Team" in June 2016. The PASD Team consists of various specialists and sub-specialists who play a role in the comprehensive management of PASD cases. The team includes specialists from Fetomaternal Division, Gynecology Oncology Division, Urology Department, Vascular Surgery Division, Diagnostic Radiology Division, Interventional Radiology Division, Intensive Care Division (ICU), Blood Transfusion Service Unit, Perinatology Division and Emergency Division.



This is our algorithm in PASD cases in emergency / elective situation based on ultrasonographic assessment as shown in (Figure 1) A placenta accreta index score was obtained and thus a high probability of invasion of the abnormal placenta or placenta accreta was obtained. The case was discussed with team of placenta accreta spectrum dis-

orders (PASD). Based on the PASD Team's agreement, a PAI score > 5 will be managed according to the path of management of PASD. For the risk management of cases with lower scores, cases are still classified as high risk cases and a doctor in charge of the patient will be determined from one of the members of the PASD Team.

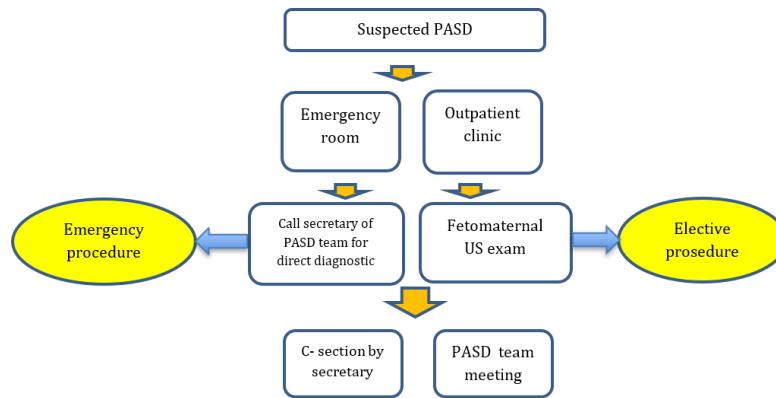


Figure 1: Algorithm in PASD Cases in Emergency/ Elective Situation Based on Ultrasonographic assessment.

Case Report

We report 3 cases of PASD that were managed by conservative surgery for the management of focal PAS using jakarta surgical uterus conservation surgery for placenta accreta (JSICA) as shown in (Table 1).

Table 1: Three cases of PASD that were managed by conservative surgery.

*In the level of ascending branch of the uterine artery, LUS: lower uterine segment.

Table 1: Three cases of PASD that were managed by conservative surgery.

No	Date	PAI	Obstetric status	Prior C- section	Technique of surgery	Surgery time	I C U admission	Intraoperative bleeding	Complication	Hemostasis uterus
1	June 22nd 2018	3	G3P2 35 wga	2x	Caesarean Section, LUS resection	2 hours	-	600	-	Tourniquet *
2	June 23rd 2018	4	G3P2 35 wga	2x	Cesarean Section continue with resection and repair of LUS	2 . 5 hours	-	850	-	Tourniquet *
3	July 31st 2019	5.5	G5P2A2 36 wga	2x	Cesarean section, anterior uterine wall resection	2 hours	-	600	-	Tourniquet *

In the first case (Figure 2), we perform corporal incision and we deliver breech of baby. On exploration, placenta was implanted on anterior corpus covering internal orifice of the uterus. Placenta was partially spontaneously detached. Tourniquet was applied at the distal part of lower uterine segment (LUS). Vesico-uterine fold was identified and opened. Placenta was adhered on the area of which suspicious of accreta. We decided to perform LUS resection (6x3 cm). Corporal incision was stitched continuously using polyglycolic acid suture (PGA) no I. We ensured no active bleeding and adequate uterine contraction.

er uterine segment (LUS) appeared bluish with hypervascularity. We suspected abnormal focal invasive placenta. We performed corporal incision and baby girl was born. On exploration, the placenta was implanted at the anterior corpus. When placenta was detached, part of placenta that was implanted on LUS cannot be detached, vesico-uterine fold was identified and opened. Tourniquet was applied at the distal part of LUS with Foley catheter. On part of LUS that suspicious of accreta, we performed LUS resection. LUS defect was repaired continuously with PGA No1. Corporal incision was stitched with PGA No 1. We ensured no active bleeding and adequate uterine contraction. Tubectomy was performed.

In the second case (Figure 3), after the peritoneum was opened, low-



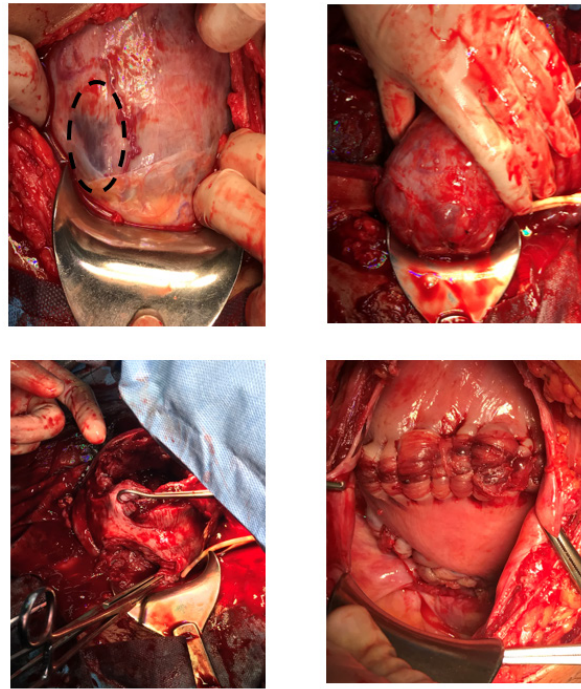


Figure 2: First case of PASD.

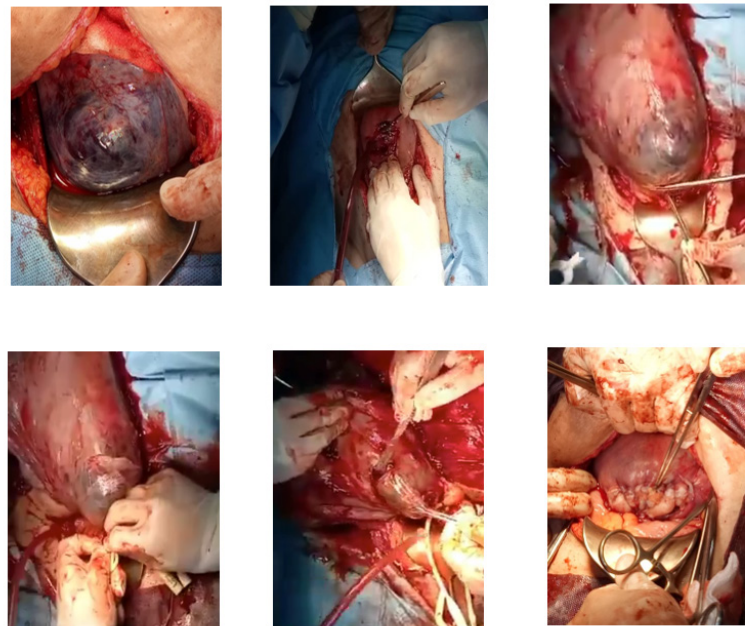


Figure 3: Second case of PASD.

In the third case (Figure 4), we found no hypervascularity on the lower uterine segment. We performed transverse corporal incision. By pulling the buttock, baby was delivered. Placenta was left in situ. Edges of uterine incision were clamped. We performed uterine traction cranially. Tourniquet was placed at the level of internal orifice/ ascending uterine vessels. Vesico-uterine fold was opened. Bladder was meticulously dissected downwards. On exploration of lower anterior uterine wall, we found no enlarged vessels or impression of placenta. We decided to perform manual removal of placenta. On exploration, we found botched placenta which was suspected due to abnormal implantation of placenta sized 8x4 cm. The operator decided to perform anterior uterine wall resection. Transverse corporal incision and lower uterine excision were sutured continuously with PGA no 1. Tourniquet was taken off. We ensured that there was no bleeding.

Follow-up and outcomes

Discussion

Conservative Management For Suspected Placenta Accreta

Placenta accreta occurs due to loss of prevention mechanism during invasion of trophoblast. There are three classifications of placental adhesion disorders: accreta, increta and percreta. Placenta accreta spectrum occurs because of neovascularisation and abnormal source of bleeding (vesicalis artery, vaginalis artery, pudenda artery). The antenatal diagnosis of placenta accreta spectrum is critical because it provides an opportunity to optimize management and outcomes [1]. Obstetric hemorrhage due to placenta accreta spectrum is one of the



important reasons of maternal mortality and morbidity [2]. If clinically or sonographically the woman is suspected antenatally of being at high risk of placenta accreta, appropriate management options should be considered, such as conservative treatment or hysterectomy, and counselling about the potential sequelae [3].

The American College of Obstetricians and Gynecologists (ACOG) generally recommends cesarean section hysterectomy in cases of placenta accreta because removal of placenta associated with significant hemorrhage [2]. As this operative procedure terminates the woman's

fertility, its performance may have devastating psychological consequences. In the vast majority of haemorrhage secondary to placenta accreta, there is little doubt that hysterectomy is the appropriate management, regardless of other factors. However, in the correct circumstances, a conservative approach may be suitable [3].

In Cipto Mangunkusumo National Hospital, Jakarta, Indonesia we calculated the percentage of conservative management vs hysterectomy for PASD as shown in (Figure 5). Conservative surgery was performed in 26% of cases of PASD.

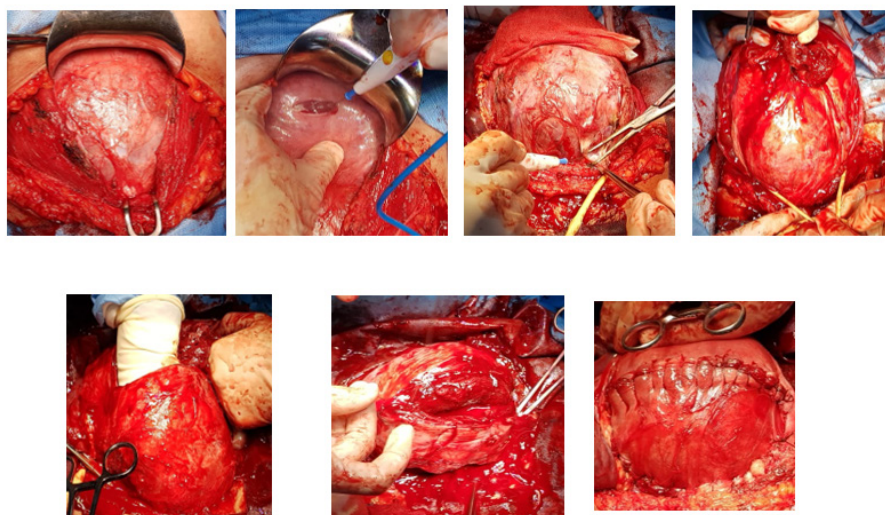


Figure 4: Third case of PASD.

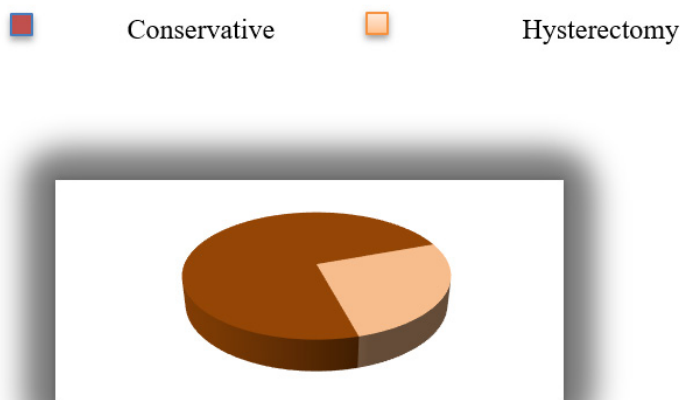


Figure 5: Percentage of conservative management vs hysterectomy for PASD.

Methods of Conservative Management

Conservative management of both abnormally adherent (placenta accreta) and invasive placenta (placenta increta and percreta) consists of all procedures that aim to avoid hysterectomy and its related morbidity and consequences. Conservative management in cases of PASD was defined by the decision of the obstetrician to leave the placenta partially or totally in situ, with no attempt to remove it forcibly. The main aim of leaving the placenta in situ versus the extirpative method is essentially to decrease the risks of severe maternal morbidity during cesarean delivery. Forcibly removing an invasive placenta with placental villi that have invaded the deep uterine vasculature increases the risks of massive obstetric hemorrhage and the need for salvation hysterectomy. Uncontrolled bleeding will lead to coagulopathy, complicate the surgical procedure, and increase the risk of injuries mainly

to the bladder and ureters and their possible long-term complications such as vesicouterine fistula [4].

Four different primary methods of conservative management have been described in the international literature:

- i. the extirpative technique (manual removal of the placenta);
 - ii. leaving the placenta in situ or the expectant approach;
 - iii. one-step conservative surgery (removal of the accreta area); and
 - iv. the Triple-P procedure (suturing around the accreta area after resection).
- In addition to leaving the placenta in situ, investigators have used adjunctive measures to diminish blood loss, hasten placental reabsorption, or both.



Techniques have included uterine devascularization with uterine artery balloon placement, embolization or ligation, and post-delivery methotrexate administration. Methotrexate use in expectant management of placenta accreta spectrum is advocated by some authors who contend that it will hasten placental involution and resorption [1].

Technique of Conservative Management For Focal Invasion of PASD in Cipto Mangunkusumo National Hospital – Faculty of Medicine Universitas Indonesia

a)1st Variation: Transverse corporal incision away from the placenta is performed. The baby is delivered by pulling or releasing the placenta as much as possible. If the area is difficult to be dissected, a catheter balloon is applied and uterine compression is performed.

b)2nd Variation: Transverse corporal incision away from the placenta is performed. The baby is delivered. Bilateral hypogastric arteries are ligated. Focal invasion correction is performed. The defects are

closed. Fimbriectomy is performed

c)3rd Variation: The supracervix is tied with a tourniquet before delivering the baby. The area of suspected placenta accreta is resected. The incision is sutured with or without sterilization procedures. In this method, fimbriectomy is performed. This method has many similarities to Surabaya Modified Procedure for Uterine Conservation (SUM-PUC).

d)4th Variation: Transverse incision at the upper border of the adherent placenta is performed. After the baby is delivered, placenta is left in the uterus. The edges of the incision are sutured. A tourniquet is placed with catheter in the supracervix. Resection of the suspected placenta accreta is performed. The incisions are sutured with or without sterilization procedures [5-9].

(Figure 6) shows the technique of conservative management for focal invasion in Cipto Mangunkusumo national hospital. Percentage of conservative management of suspected placenta accreta in Cipto Mangunkusumo National Hospital is shown in (Figure 7).

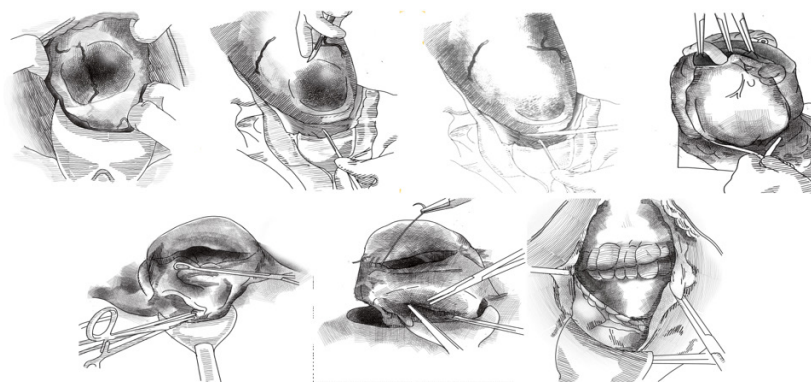


Figure 6: Technique of conservative management for focal invasion of PASD in Cipto Mangunkusumo National Hospital – Faculty of Medicine Universitas Indonesia.

Conservative management of suspected placenta accreta in Cipto Mangunkusumo National Hospital (n:20)

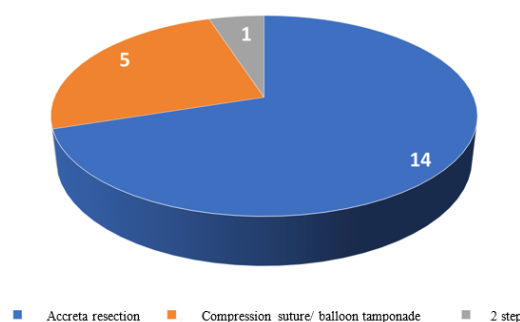


Figure 7: Percentage of conservative management of suspected placenta accreta in Cipto Mangunkusumo National Hospital.

Declarations

Acknowledgement

The authors would like to thank department of obstetry and gynecology Faculty of Medicine University of Indonesia.

Financial Disclosure or Funding

The authors received no financial support for the research, authorship, and/or publication of this article.

Conflict of Interest

There are no conflict of interests to declare.

Informed Consent

The patients had given consent to participate in this case report.

List of abbreviations

(ACOG): The American College of Obstetricians and Gynecol-



ogists; (AIP): Abnormally invasive placenta; (ICU): Intensive care unit; (JSICA): Jakarta closure technique conservative surgery for AIP; (LUS): Lower uterine segment; (PASD): Placenta accreta spectrum disorders; (PGA): Polyglycolic acid suture; (SUMPUC): Surabaya-Modified Procedure for Uterine Conservation.

References

1. Bhide A, Arulkumaran S, Damania KR, Daftary SN Ante partum haemorrhage. Placenta accrete. Practical Guide to High risk in pregnancy and Delivery, A south Asian Perspective 4th edition, Chapter 10; pg 158.
2. Kayem G, Davy C, Goffinet F, Thomas C, Clement D et.al (2004) Conservative versus Extirpative management in cases of placenta accrete. American College of Obstetricians and Gynecologists 104(3): 531-536.
3. Eller AG, Porter TF, Soisson P, Silver RM. University of Utah Journal compilation a RCOG 2009 BJOG An International Journal of Obstetrics and Gynaecology.
4. Fitzpatrick KE, Sellers S, Spark P, Kurinczuk JJ, Brocklehurst P, et.al (2014) The management and outcomes of placenta accrete, increta and percreta in the UK: a population-based descriptive study. BJOG 121: 62-71.
5. Oyelese Y, Smulian JC (2006) Placenta previa, placenta accreta, and vasa previa. Obstet Gynecol 107: 927-941.
6. Silver RM, Landon MB, Rouse DJ, Leveno KJ, Spong CY, et. al (2006) Maternal morbidity associated with multiple repeat cesarean deliveries. Obstet Gynecol 107: 1226-1232.
7. Miller DA, Chollet JA, Goodwin TM (1997) Clinical risk factors for placenta previa-placenta accreta. Am J Obstet Gynecol 177: 210-214.
8. Wu S, Kocherginsky M, Hibbard JU (2005) Abnormal placentation: twenty- year analysis. Am J Obstet Gynecol 192: 1458-1461.
9. Dr. Cipto Mangunkusumo (2018) Panduan praktik klinis plasenta akreta RSUPN.

